

Experience With J-Plasma Device in Achieving Complete Cytoreduction in Patients With Ovarian Cancer

CHRISTOS IAVAZZO, ALEXANDROS FOTIOU, KALLIOPI KOKKALI and GEORGE VORGAS

Gynecologic Oncology Department, "Metaxa" Memorial Cancer Hospital of Piraeus, Piraeus, Greece

Abstract. *Background/Aim:* Ovarian cancer remains one of the most lethal malignancies in women. Optimal surgical cytoreduction is the most important prognostic factor of survival in patients with advanced ovarian cancer. The helium gas plasma device (J-Plasma) has recently been introduced into surgical treatment of these patients with some promising results. The aim of this study was to evaluate the utility of J-Plasma in the debulking surgery of patients with ovarian cancer. *Patients and Methods:* A single center retrospective analysis of the characteristics of patients with ovarian cancer who had cytoreductive surgery with the use of J-Plasma device from January of 2020 until July of 2022 was conducted. *Results:* A total of 13 patients were included in our study. Six patients were treated with primary debulking surgery, whereas seven underwent interval debulking surgery after neoadjuvant chemotherapy. Complete cytoreduction was achieved in nine patients (64%), and CC-1 in four patients. Most of the patients did not face any major complications; only 1 patient suffered from small bowel fistula that needed relaparotomy. *Conclusion:* J-Plasma can safely be used in ovarian cancer debulking surgeries performed by gynecologic oncologists in tertiary centres. This technology can safely increase the complete cytoreduction rates.

Correspondence to: Alexandros Fotiou (ORCID ID: 0000-0003-2428-3992), MD, PhD, Department of Gynecologic Oncology, Metaxa Memorial Cancer Hospital, 51 Botasi Str., Piraeus, Greece. Tel: +30 6982832287, e-mail: alexandrosfotiou92@gmail.com

Key Words: Ovarian cancer, J-Plasma, cytoreductive surgery, helium gas plasma, complete cytoreduction.

©2023 International Institute of Anticancer Research
www.iiar-anticancer.org



This article is an open access article distributed under the terms and conditions of the Creative Commons Attribution (CC BY-NC-ND) 4.0 international license (<https://creativecommons.org/licenses/by-nc-nd/4.0>).

Epithelial ovarian cancer remains one of the most lethal malignancies in women. Based on GLOBOCAN 2020, ovarian cancer is third in incidence and second regarding the mortality among all gynecological malignancies. It is estimated that 313.959 new epithelial ovarian cancer cases were diagnosed in 2020 worldwide, and 207.252 deaths occurred by this cause (1). Most of the new cases are diagnosed with advanced stage disease after dissemination to the peritoneal cavity, leading to a 5-year survival rate of 30.8% (2). Treatment options for advanced stage patients include upfront cytoreductive surgery supplemented with platinum-based adjuvant chemotherapy or neoadjuvant chemotherapy combined with bevacizumab followed by interval debulking surgery (3, 4). The aim of all treatment options is complete cytoreduction based on macroscopic disease remained into the peritoneal cavity after the cytoreductive surgery, as complete resection of all macroscopic disease has been shown to be the most important prognostic factor in advanced stage ovarian cancer (5). Furthermore, a secondary objective remains the minimization of intra- and post-operative complications that would be faced by selecting the optimal treatment for any patient. This could be achieved by evaluating several preoperative markers as several published articles have demonstrated (6).

A lot of studies have investigated several different surgical techniques and technologies that aim to complete cytoreduction. Among them, the role of neutral argon plasma (PlasmaJet) in advanced ovarian cancer cytoreductive surgeries has been studied adequately (7-9). Most of these studies concluded that the use of neutral argon plasma is associated with better surgical outcomes, higher rates of complete cytoreduction, and longer disease-free and overall survival.

On the contrary, the utility of helium gas plasma (J-Plasma), which combines the properties of helium plasma with a proprietary radiofrequency waveform, has not been widely discussed in the literature (10). The device combines the effects of helium heated plasma fueled by electrosurgical energy leading to precise and predictable effects with minimal depth of diffusion of energy and therefore, no collateral damage to surrounding healthy tissue. Based on its technical specifications,

the J-Plasma even in its highest settings has a maximum depth spread of approximately 2 mm and a maximum lateral spread of 4 mm. This unique feature is extremely beneficial in surgical procedures that need precision where the pathologic tissue must be separated from vital organs that should be left unharmed, such as peritonectomies near bowel or diaphragmatic stripping (11). This study investigated the utility of helium gas plasma in ovarian cancer cytoreductive surgery.

Patients and Methods

Patient characteristics. We report a single center retrospective analysis of the data of patients with ovarian cancer that were admitted in the Gynecologic Oncology Department of “Metaxa” Memorial Cancer Hospital of Piraeus from January of 2020 until July of 2022 and underwent either primary or interval cytoreductive surgery with the use of J-Plasma. Only patients that were treated surgically while using J-Plasma were included in our study.

A gynecologic oncologist was always one of the surgeons. All surgeons were trained to perform operations with the J-Plasma during the cytoreductive surgery, and someone with experience with J-Plasma was always present.

Patient characteristics such as age, cancer antigen 125 (CA-125), human epididymis protein-4 (HE-4), computed tomography (CT) findings, FIGO stage, histologic type, type of surgical procedure (primary or interval debulking surgery), completeness of cytoreduction (CC-score), intraoperative and postoperative complications were documented.

All patients that were eligible for undergoing cytoreduction surgery, either primary or interval, were included. Patients with recurrent disease, non-epithelial ovarian cancer, borderline tumors, or ovarian metastasis of another primary tumor (Krukenberg disease) were excluded from our retrospective analysis.

All patients provided written informed consent. All procedures performed in this study were in accordance with the ethical standards of the institutional research committee and with the 1964 Helsinki and its later amendments.

Preoperative management. Preoperative imaging with CT scans were performed for all the included patients who underwent primary or interval debulking surgery. Measurement of CA-125 and HE-4 was performed preoperatively.

Treatment. Treatment options included primary cytoreductive surgery followed by 6 cycles of adjuvant chemotherapy (carboplatin, paclitaxel, and bevacizumab) or 3 or 4 cycles neoadjuvant chemotherapy (carboplatin, paclitaxel, and bevacizumab) followed by interval debulking surgery and 3 cycles adjuvant chemotherapy with the same regimens. Patients with tumor BRCA mutations received maintenance therapy with poly (ADP-ribose) polymerase inhibitor (12). Patients were subgrouped based on the time of their surgery into two groups:

1. Primary debulking surgery (PDS) group, where patients were treated surgically upfront and afterwards, they received adjuvant chemotherapy treatment and
2. Interval debulking surgery (IDS) group, where patients were treated surgically after 3 or 4 cycles of neo-adjuvant chemotherapy. Surgical procedures included total hysterectomy, bilateral salpingo-oophorectomy, radical omentectomy, diaphragmatic stripping if

Table I. Patient characteristics.

	PDS (n=6)	IDS (n=7)
Age (mean)	64.7 years	68.7 years
BMI (mean)	32.8 kg/m ²	34.3 kg/m ²
ECOG status (median)	1	1
FIGO stage	IA: 2 IC: 1 IIB: 1 IVA: 2	IIIC: 5 IVA: 2
CA-125 preoperatively (mean)	498.7	377.7
CA-125 at diagnosis (for IDS group) (mean)	-	1,841.4
HE-4 preoperatively (mean)	166.3	413.3
HE-4 at diagnosis (for IDS group) (mean)	-	867.3

PDS: Primary debulking surgery; IDS: interval debulking surgery; BMI: body mass index; CA-125: cancer antigen 125; HE-4: human epididymis protein 4.

necessary, total parietal peritonectomy and mesenteric peritonectomy if there was any visible or palpable tumor, dissection of small intestine and colon if necessary, and dissection of bulky lymph nodes if they were recognized.

Completeness of cytoreduction (CC) was documented based on the CC-score by Sugarbaker’s criteria. CC 0 indicated no residual peritoneal disease, CC 1 less than 2.5 mm, CC 2 residual disease between 2.5 mm and 2.5 cm, while CC 3 indicated presence of residual tumor with a diameter more than 2.5 cm (13). Estimated blood loss was calculated according to hemoglobin difference between preoperative and first postoperative day blood samples. Length of hospital stay was defined as the postoperative days until discharge. Complications were classified based on Clavien–Dindo classification (14).

Primary endpoints of this retrospective study were the completeness of cytoreduction, while secondary outcomes included duration of surgery, blood loss, length of hospital stay, and complication rate.

Statistical analysis. Statistical analysis was performed using SPSS v.22.0 statistical software for Windows (SPSS, Chicago, IL, USA). Descriptive statistics were used to describe the clinical, demographic, and surgical variables. Quantitative variables have been summarized by their median, mean and range.

Results

In total, 13 patients were treated for ovarian cancer with cytoreductive surgery using J-Plasma. Among them six patients were treated with primary cytoreductive surgery (PDS) followed by adjuvant chemotherapy, while seven patients were treated with interval debulking surgery (IDS) after 3 or 4 cycles of neoadjuvant chemotherapy. Patient characteristics are summarized in Table I.

Regarding the surgical outcomes, complete cytoreduction (CC 0) based on Sugarbaker’s criteria was achieved in nine patients, whereas CC 1 in four patients. Surgical procedures

Table II. *Surgical procedures and outcomes.*

	PDS (n=6)	IDS (n=7)
Completeness of cytoreduction	CC 0: 3 CC 1: 3	CC 0: 6 CC 1: 1
Surgical procedures	USO: 2 TAH+BSO: 4 Radical omentectomy: 6 PLND: 4 PaLND: 4 TPP: 4 TMP: 2 TDP: 4 Splenectomy: 1 Nonanatomic HWR: 2	TAH+BSO: 7 Radical omentectomy: 7 TPP: 3 TDP: 1 Sigmoidectomy: 1
Operative time (mean)	287 min	189 min
Blood loss (mean)	3.6 g/dl	2.7 g/dl

USO: Unilateral salpingo-oophorectomy; TAH+BSO: total abdominal hysterectomy and bilateral salpingo-oophorectomy; PLND: pelvic lymph node dissection; PaLND: para-aortic lymph node dissection; TPP: total parietal peritonectomy; TMP: total mesenteric peritonectomy; TDP: total diaphragmatic peritonectomy; HWR: hepatic wedge resection.

are documented in Table II. Median operative time was 287 min in the PDS group whereas the IDS group had significantly shorter operative time (189 min). Furthermore, blood loss was 3.6 g/dl in the PDS group and 2.7 g/dl in IDS group. Surgical outcomes are summarized in Table II.

Regarding complications, one patient suffered from small bowel fistula that needed relaparotomy. Complications according to Clavien–Dindo classification are summarized in Table III. There were no urological complications, iatrogenic diaphragmatic injuries, or patients requiring pleural drainage.

Discussion

Our study aimed to evaluate the surgical outcomes from the usage of J-Plasma in the surgical treatment of patients with ovarian cancer patients' surgical treatment. Based on our experience, the use of J-Plasma allowed us to succeed complete cytoreduction in more ovarian cancer patients without higher rates of complications.

The helium heated plasma is an innovative electrosurgical device recently approved by FDA that uses the power of helium gas plasma for precise surgical treatment of several pathologies. This electrosurgical instrument allows a precise coagulation and dissection of pathologic tissue with minimal depth of diffusion of energy in the nearby tissue. Therefore, there is a reduced risk of injury to adjacent vital organs or healthy tissues. Moreover, J-Plasma device, due to its attributes, allows for excision of abdominal adhesions with reduced risk for iatrogenic injury. Table IV compares the characteristics of different electrosurgical devices.

As Table IV demonstrates, thermal spread of J-Plasma is the least among all the commonly used electrosurgical

Table III. *Complications according to Clavien–Dindo classification.*

PDS (n=6)	IDS (n=7)
Clavien–Dindo I: 6	Clavien–Dindo I: 7
Clavien–Dindo II: 3	Clavien–Dindo II: 4
Clavien–Dindo III: 1	

PDS: Primary debulking surgery; IDS: interval debulking surgery.

devices (15). This minimal thermal spread was confirmed by Pedrosa *et al.* in 2017 (16). In this article, the authors concluded that J-Plasma did not exceed 2 mm thermal spread even at a maximum setting of 100% power after five seconds on several tissues, such as ovarian and uterine tissue. Moreover, they demonstrated that even exposure for up to 30 seconds did not increase the depth of thermal injury more than 2.84 mm, a measurement that remains less than the conventional monopolar electrosurgical pencil (16).

This retrospective study is only the third retrospective analysis in the current published literature that evaluates the possible efficacy of helium gas plasma (J-Plasma) in ovarian cancer surgical treatment.

Recently, Theodoulidis *et al.* in their retrospective analysis of the surgical treatment of patients with advanced ovarian cancer concluded that J-Plasma could be safely used in diaphragmatic resection with no J-Plasma-related complications and no defect in diaphragmatic integrity (17). These results are confirmed by our study, despite the smaller number of diaphragmatic resections on our cohort. We must also highlight that in our cohort population, J-Plasma was safely used in patients that underwent total mesenteric

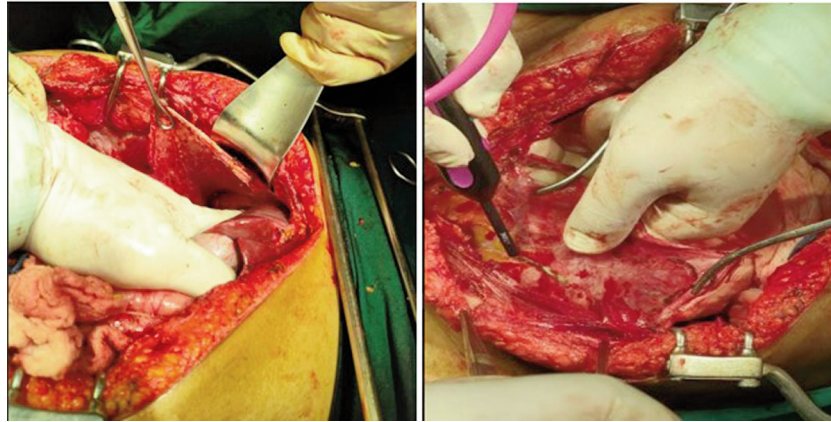


Figure 1. Resection of parietal and diaphragmatic peritoneum.

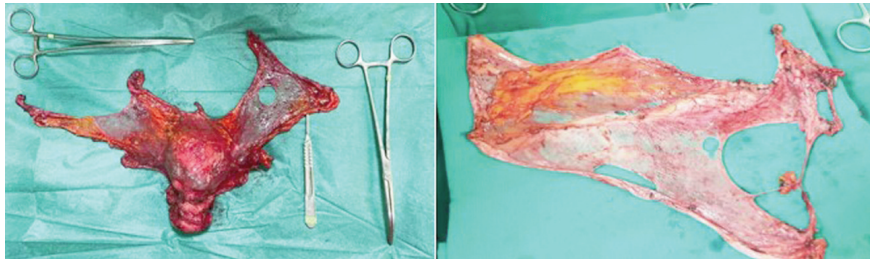


Figure 2. Specimens of total abdominal hysterectomy combined with total parietal peritonectomy and total mesenteric peritonectomy.

Table IV. Comparison of different electro-surgical devices.

Device	Energy source	Thermal spread	Energy control	Grounding pad
J-Plasma	Helium Plasma (RF)	0.2 mm	Continuous or pulsed	No
Electrosurgical Monopolar Pencil	Electrosurgical (RF)	8.5 mm	Continuous	Yes
Ultrasonic Energy	Frictional heat (high frequency)	2-3 mm	Continuous or pulsed	No
Argon Beam	Argon Plasma (RF)	1.4 mm	Continuous	Yes

RF: Radiofrequency.

peritonectomy and total parietal peritonectomy (Figure 1, Figure 2, and Figure 3).

Moreover, Gueli Alletti *et al.* reported their experience in either laparotomic or laparoscopic surgical treatment of gynecological malignancies. According to their results, J-Plasma was applicable when the surgeons were facing disease on the bowel serosa without infiltration of the intestinal wall, on the diaphragmatic peritoneum and on the intestinal mesentery. Furthermore, in Gueli Alletti *et al.* concluded that surgeons reached the learning curve after three procedures; a statement that was confirmed by our initial experience with J-Plasma device (18).

The use of cold atmospheric helium plasma has been recently introduced into the surgical treatment for several different pathologies from several different specialties. Devices that use this kind of technology such as J-Plasma have the advantage of minimal lateral and depth of thermal spread in a variety of tissues compared to different devices using conventional electro-surgical technology or even neutral argon plasma (19). This important feature gives the opportunity in surgeries where peritonectomies are required to complete cytoreduction such as ovarian cancer debulking surgeries, to be performed without any collateral damage to nearby organs.

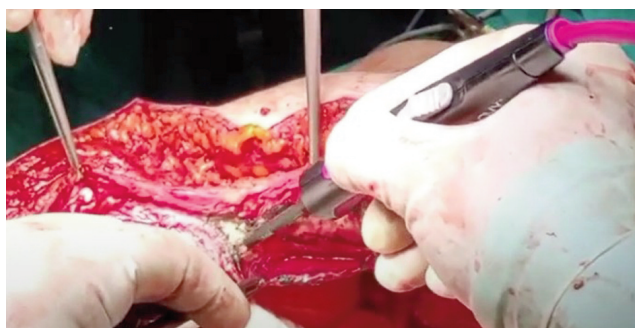

Figure 3. Application of J-Plasma in pelvic parietal peritonectomy.

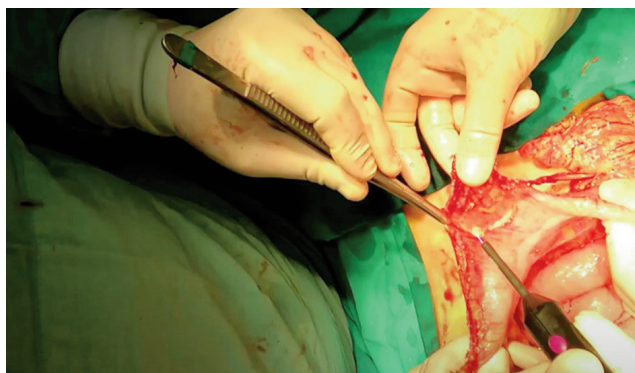


Figure 4. Application of J-Plasma in omentectomy.

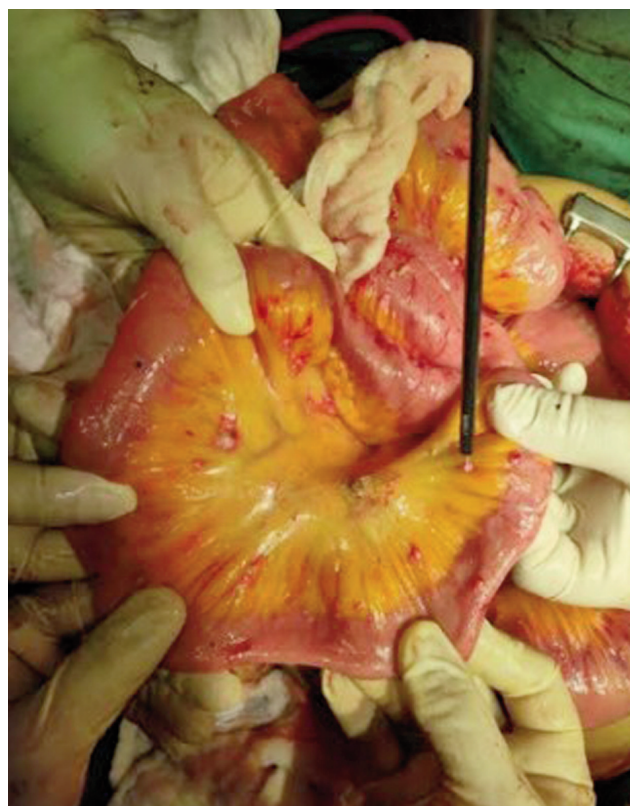

Figure 5. Resection of lesions on intestinal mesentery.

Several novel surgical devices have been introduced in debulking surgeries for ovarian cancer. Among them, the application of neutral argon plasma (PlasmaJet) has been increasingly used. Several articles have investigated the utility of neutral argon plasma with some encouraging results. More specifically, a randomized controlled trial conducted in the Netherlands by Nieuwenhuyzen-de Boer *et al*. concluded that the adjuvant use of PlasmaJet during the cytoreduction in patients with advanced ovarian cancer resulted in a higher rate of complete cytoreduction and higher quality of life at 6 months after surgery (7). Interestingly, the group of patients that were treated with PlasmaJet neither faced more complications nor needed more blood transfusion. Moreover, even though the difference was not statistically significant, in the intervention group (PlasmaJet) the number of colostomies was lower (6.5% vs. 12.7%) (7). Until now, such a randomized control trial is missing from the current literature regarding the utility of J-Plasma in advanced ovarian cancer surgical treatment.

To our experience, the application of J-Plasma outperforms the classic electrocoagulation technology in circumstances where there are many small malignant implants on the small intestines or on the large bowel (Figure 4). In the past, in order

to achieve complete cytoreduction in such patients a bowel resection was inevitable. The use of plasma energy facilitates the removal of disease in the bowel serosa (rectal shaving) (18). With the use of J-Plasma such lesions on the bowel's mesentery could be removed without damaging the blood supply and without the need of bowel resection and anastomoses, procedures that add surgical time and possible intra- and postoperative complications such as leakage (Figure 5).

Our study has several limitations, starting from the small number of patients included, which indicates however the innovative nature of our approach and underlines the necessity of more prospective randomized controlled trials and metaanalyses to clarify the efficacy and safety of the J-Plasma use in ovarian cancer surgical treatment. Moreover, the retrospective character of our study is also a limitation.

Conclusion

Summarizing, our study supports that J-Plasma can safely be used in ovarian cancer debulking surgeries performed by gynecologic oncologists in tertiary centers. The addition of this technology can increase the complete cytoreduction rates without any increase in the rate of complications.

Conflicts of Interest

All the Authors declare no conflicts of interest in relation to this study.

Authors' Contributions

Christos Iavazzo and George Vorgias contributed to the study conception and design. Material preparation, data collection and analysis were performed by Alexandros Fotiou and Kalliopi Kokkali. The first draft was written by Alexandros Fotiou. All Authors commented on previous versions of the article, and read and approved the final manuscript.

References

- Sung H, Ferlay J, Siegel RL, Laversanne M, Soerjomataram I, Jemal A and Bray F: Global cancer statistics 2020: GLOBOCAN estimates of incidence and mortality worldwide for 36 cancers in 185 countries. *CA Cancer J Clin* 71(3): 209-249, 2021. PMID: 33538338. DOI: 10.3322/caac.21660
- CRUK. Cancer statistics: ovarian cancer survival statistics. 2019. Available at: <https://www.cancerresearchuk.org/health-professional/cancer-statistics/statistics-by-cancer-type/ovarian-cancer/survival> [Last accessed on February 25, 2023]
- Colombo N, Sessa C, du Bois A, Ledermann J, McCluggage WG, McNeish I, Morice P, Pignata S, Ray-Coquard I, Vergote I, Baert T, Belaroussi I, Dashora A, Olbrecht S, Planchamp F, Querleu D and ESMO-ESGO Ovarian Cancer Consensus Conference Working Group: ESMO-ESGO consensus conference recommendations on ovarian cancer: pathology and molecular biology, early and advanced stages, borderline tumours and recurrent disease†. *Ann Oncol* 30(5): 672-705, 2019. PMID: 31046081. DOI: 10.1093/annonc/mdz062
- du Bois A, Baert T and Vergote I: Role of neoadjuvant chemotherapy in advanced epithelial ovarian cancer. *J Clin Oncol* 37(27): 2398-2405, 2019. PMID: 31403864. DOI: 10.1200/JCO.19.00022
- du Bois A, Reuss A, Pujade-Lauraine E, Harter P, Ray-Coquard I and Pfisterer J: Role of surgical outcome as prognostic factor in advanced epithelial ovarian cancer: a combined exploratory analysis of 3 prospectively randomized phase 3 multicenter trials: by the Arbeitsgemeinschaft Gynaekologische Onkologie Studiengruppe Ovarialkarzinom (AGO-OVAR) and the Groupe d'Investigateurs Nationaux Pour les Etudes des Cancers de l'Ovaire (GINECO). *Cancer* 115(6): 1234-1244, 2009. PMID: 19189349. DOI: 10.1002/cncr.24149
- Bacalbasa N, Balescu I, Dimitriu M, Iliescu L, Diaconu C, Dima S, Vilcu M and Brezean I: The influence of the preoperative status on the risk of postoperative complications after cytoreductive surgery for advanced-stage ovarian cancer. *In Vivo* 34(2): 839-844, 2020. PMID: 32111792. DOI: 10.21873/invivo.11846
- Nieuwenhuijzen-de Boer GM, Hofhuis W, Reesink-Peters N, Willemssen S, Boere IA, Schoots IG, Piek MJ, Hofman LN, Beltman JJ, van Driel WJ, Werner HMJ, Baalbergen A, van Haften-de Jong AMLD, Dorman M, Haans L, Nedelcu I, Ewing-Graham PC and van Beekhuizen HJ: Adjuvant use of PlasmaJet device during cytoreductive surgery for advanced-stage ovarian cancer: Results of the PlaComOv-study, a randomized controlled trial in the Netherlands. *Ann Surg Oncol* 29(8): 4833-4843, 2022. PMID: 35552938. DOI: 10.1245/s10434-022-11763-2
- Panuccio E, Leunen K, Van Nieuwenhuysen E, Neven P, Lambrechts S and Vergote I: Use of PlasmaJet for peritoneal carcinomatosis in ovarian cancer. *Int J Gynecol Cancer* 26(8): 1521-1524, 2016. PMID: 27488213. DOI: 10.1097/IGC.0000000000000788
- Cordeiro Vidal G, Babin G, Querleu D and Guyon F: Primary debulking surgery of the upper abdomen and the diaphragm, with a plasma device surgery system, for advanced ovarian cancer. *Gynecol Oncol* 144(1): 223-224, 2017. PMID: 27836207. DOI: 10.1016/j.ygyno.2016.10.030
- Gay-Mimbrera J, García MC, Isla-Tejera B, Rodero-Serrano A, García-Nieto AV and Ruano J: Clinical and biological principles of cold atmospheric plasma application in skin cancer. *Adv Ther* 33(6): 894-909, 2016. PMID: 27142848. DOI: 10.1007/s12325-016-0338-1
- Nutis M: J-Plasma: Surgical treatment of endometriosis. Available at: http://apyxmedical.com/wp-content/uploads/2018/12/wp-j-plasma_surgical_treatment_of_endometriosis.pdf [Last accessed on March 3, 2023]
- Banerjee S, Moore KN, Colombo N, Scambia G, Kim BG, Oaknin A, Friedlander M, Lisysanskaya A, Floquet A, Leary A, Sonke GS, Gourley C, Oza A, González-Martín A, Aghajanian C, Bradley WH, Holmes E, Lowe ES and DiSilvestro P: Maintenance olaparib for patients with newly diagnosed advanced ovarian cancer and a BRCA mutation (SOLO1/GOG 3004): 5-year follow-up of a randomised, double-blind, placebo-controlled, phase 3 trial. *Lancet Oncol* 22(12): 1721-1731, 2021. PMID: 34715071. DOI: 10.1016/S1470-2045(21)00531-3
- Sugarbaker PH: Peritoneal carcinomatosis: Principles of management. Paul H (ed.). Boston, MA, USA, Kluwer Academic Publishers, 1996.
- Dindo D, Demartines N and Clavien PA: Classification of surgical complications: a new proposal with evaluation in a cohort of 6336 patients and results of a survey. *Ann Surg* 240(2): 205-213, 2004. PMID: 15273542. DOI: 10.1097/01.sla.0000133083.54934.ae
- McCoy C: J-Plasma's role in treating and preventing intra-abdominal adhesions. Available at: http://apyxmedical.com/wp-content/uploads/2018/12/wp-j-plasma_role_in_treating_and_preventing_intraabdominal_adhesions.pdf [Last accessed on March 3, 2023]
- Pedroso JD, Gutierrez MM, Volker KW and Howard DL: Thermal effect of J-Plasma® energy in a porcine tissue model: Implications for minimally invasive surgery. *Surg Technol Int* 30: 19-24, 2017. PMID: 28693047.
- Theodoulidis V, Prodromidou A, Stamatakis E, Alexakis N, Rodolakis A and Haidopoulos D: Application of J-Plasma in the excision of diaphragmatic lesions as part of complete cytoreduction in patients with advanced ovarian cancer. *Mol Clin Oncol* 17(1): 113, 2022. PMID: 35747592. DOI: 10.3892/mco.2022.2546
- Gueli Alletti S, Rosati A, Capozzi VA, Pavone M, Gioè A, Cianci S, Chiantera V, Vizzielli G, Scaglione G, Fagotti A and Scambia G: Use of laparoscopic and laparotomic J-Plasma handpiece in gynecological malignancies: Results from a pilot study in a tertiary care center. *Front Oncol* 12: 868930, 2022. PMID: 35837114. DOI: 10.3389/fonc.2022.868930
- Gentile RD: Cool atmospheric plasma (J-Plasma) and new options for facial contouring and skin rejuvenation of the heavy face and neck. *Facial Plast Surg* 34(1): 66-74, 2018. PMID: 29409106. DOI: 10.1055/s-0037-1621713

Received February 15, 2023

Revised March 4, 2023

Accepted March 6, 2023