

# Fibulo-Scapho-Lunate Arthrodesis With Free Vascularized Fibular Graft for a Japanese Kyudo Archer With Osteosarcoma of the Left Distal Radius: A Case Report

NOBUYUKI SASAKI<sup>1</sup>, RYOICHI KAWAKAMI<sup>1,2,3</sup>, NARIHIRO TOSHIKI<sup>1,4</sup>, HITOSHI YAMADA<sup>1,5</sup>, MICHIIYUKI HAKOZAKI<sup>1,6</sup> and SHIN-ICHI KONNO<sup>1</sup>

<sup>1</sup>Department of Orthopaedic Surgery, Fukushima Medical University School of Medicine, Fukushima, Japan;

<sup>2</sup>Department of Traumatology and Reconstructive Surgery, Fukushima Medical University School of Medicine, Fukushima, Japan;

<sup>3</sup>Kawakami Orthopaedic Clinic, Fukushima, Japan;

<sup>4</sup>Department of Hand and Limb Reconstructive Surgery, Fukushima Medical University School of Medicine, Fukushima, Japan;

<sup>5</sup>Department of Musculoskeletal Oncology and Metabolic Bone Disease Research, Fukushima Medical University School of Medicine, Fukushima, Japan;

<sup>6</sup>Higashi-Shirakawa Orthopaedic Academy, Fukushima Medical University School of Medicine, Fukushima, Japan

**Abstract.** *Background:* Recent progress in the chemotherapy and surgical procedures for osteosarcoma have enabled the preservation of limb function even when cancer occurs in the distal radius, a rare primary site of osteosarcoma. *Case Report:* We describe a case of osteosarcoma that occurred in an 18-year-old, male Kyudo (Japanese archery) archer's left distal radius. Since the patient desired to resume Kyudo and the left hand was quite important for gripping a bow, we chose partial wrist arthrodesis (fibulo-scapho-lunate arthrodesis) with free vascularized fibular grafting (FVFG) as the reconstruction procedure following wide resection. After the wide resection, the major axis of bone defect was 8 cm. We

harvested a free vascularized fibular graft with fascio-cutaneous flap with wide fascia to reconstruct the gliding surface of the extensor tendon. Fibula-proximal radius and fibulo-scapho-lunate fixation was performed by locking plates individually. Vascular anastomosis was performed between the radial artery and peroneal artery in a flow-through manner. Two peroneal veins were anastomosed with the radial vein and cephalic vein. *Conclusion:* Fibulo-scapho-lunate arthrodesis with FVFG may provide satisfied stability and function even in a Kyudo archer. The patient obtained sufficient wrist stability and grip strength, and could resume Kyudo.

*Correspondence to:* Dr. Nobuyuki Sasaki, Department of Orthopaedic Surgery, Fukushima Medical University School of Medicine, 1 Hikarigaoka, Fukushima City, Fukushima 960-1295, Japan. Tel: +81 245471276, Fax: +81 245485505, e-mail: nobuyuki@fmu.ac.jp

**Key Words:** Free vascularized fibular grafting, partial wrist arthrodesis, fibulo-scapho-lunate arthrodesis, osteosarcoma, Kyudo archer.

©2022 International Institute of Anticancer Research  
www.iiar-anticancer.org



This article is an open access article distributed under the terms and conditions of the Creative Commons Attribution (CC BY-NC-ND) 4.0 international license (<https://creativecommons.org/licenses/by-nc-nd/4.0>).

As the result of the recent progress in the multidisciplinary treatment of osteosarcoma, the 5-year disease-free survival rate is expected to be around 70% in cases with localized disease (1), and success rate of limb-sparing surgery reaches >90% (2), which leads to an improved quality of life (QOL) of patients with osteosarcoma (3).

Although osteosarcoma of the distal radius is rare and accounts for only 0.8% (4), the loss of wrist function caused by wide resection leads to a lower QOL. Therefore, the functional reconstruction of the wrist joint, including the forearm rotation and joint stability, as well as finger motion should be considered. Concerning the reconstruction of the bone defect, free vascularized fibular grafting (FVFG) is a superior procedure compared to simple bone grafting, because it can reconstruct the skin and soft tissue including the gliding floor of the extensor tendons of the hand, as well as the bone defect. The transplantation of living subcutaneous tissue

reduces the adhesion of the tendons, and allows good function of the extensor and flexor tendons of the hand.

Concerning the reconstruction of the wrist joint function, three types of joint reconstructions are available: total wrist fusion, partial wrist fusion, and fibula head grafting arthroplasty (5-9). Among these options, total wrist fusion sacrifices the range of motion, and fibular head grafting causes instability of the wrist joint. Conversely, reconstruction with partial wrist fusion has the potential to preserve the range of motion and achieve stability of the wrist joint.

We report a case of osteosarcoma of the left distal radius that occurred in a young athlete of Kyudo, Japanese archery. Since he ambioned to continue Kyudo, we performed fibulo-scapho-lunate arthrodesis with FVFG after wide resection for reconstruction of his left wrist, which is the key joint for the grip of Japanese bow, to satisfy delicate movements of grasping and handling. Informed consent for the publication of this case report was obtained from the patient.

### Case Report

The patient was an 18-year-old male and a member of a university Kyudo team. He was diagnosed with a conventional osteosarcoma of the left distal radius (Figure 1A and B) without distant metastasis (Enneking stage IIB). After five courses of neoadjuvant chemotherapy with cisplatin (CDDP) and doxorubicin (DXR), surgery was performed. The distal radius was widely resected up to 8 cm proximal, including the articular surface and the gliding floor of the extensor tendon (Figure 2A, B and C). To reconstruct the gliding floor of the extensor tendon, we harvested an ipsilateral FVFG with the large adipo-fascial flap with wide fascia beforehand. At first, the cut surfaces of the distal end of the radius and the proximal end of the fibular graft were fixed with an LCP small plate (Depuy Synthes, West Chester, PA, USA). Thereafter, fibulo-scapho-lunate arthrodesis was performed; the proximal cartilage surface of the scaphoid and lunate were decorticated, and the scaphoid and lunate were fixed with the distal cut surface of the fibular graft using a VA LCP Two Column Volar Distal Radius plate (Depuy Synthes). For reconstructing the gliding floor of the extensor tendon, the dorsal plate of the distal radius was covered with adipofascial tissue attached with the FVFG (Figure 3A and B). The peroneal artery was anastomosed to the radial artery in a flow-through fashion. Two peroneal veins were anastomosed in an end-to-end fashion with the radial vein and cephalic vein (Figure 4). The radius and ulna were temporarily fixed with a kirschner wire for 8 weeks (Figure 5A and B).

As a post-surgical treatment, adjuvant chemotherapy with high-dose methotrexate (MTX), DXR, and CDDP was started 2 weeks after the operation. Finger and wrist motion exercises including tendon gliding exercises started 1 week

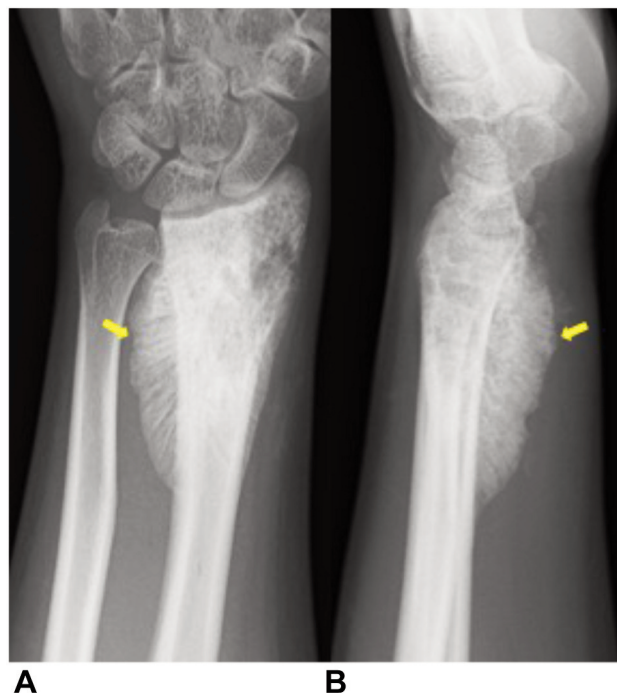
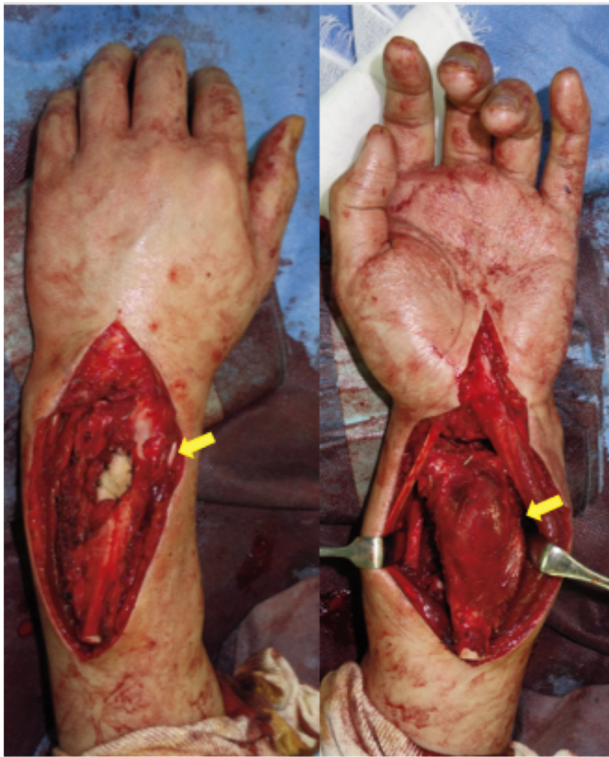

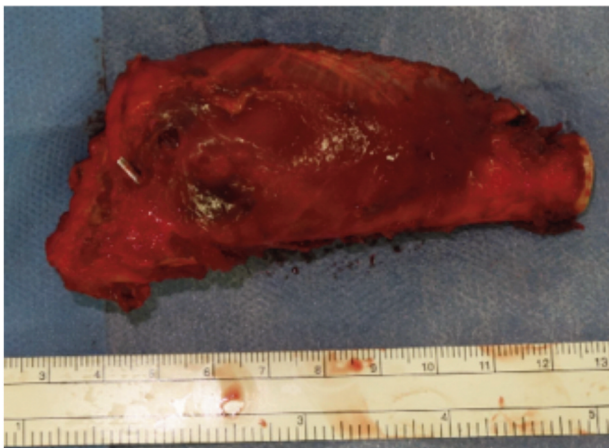
Figure 1. X-ray showing the osteosarcoma of the left distal radius (A, anteroposterior view; B, lateral view) with extraosseous extension (yellow arrows).

after the surgery. The outrigger splint was used to extend the metacarpophalangeal (MP) joints passively from 2 to 8 weeks postoperatively. Forearm supination and pronation exercises were started after the kirschner wire removal, which fixed the radius and ulna temporarily. Weight bearing was allowed gradually 14 weeks postoperatively.

Complete bone union was confirmed by computed tomography (CT) at 5 months postoperatively. Ten months after the surgery, the patient finished all the postoperative treatment and could resume Kyudo. The patient's wrist pain was relieved, and an appropriate fibulo-ulnar gap was observed at the X-ray 16 months postoperatively (Figure 6A and B). At the final follow up, 44 months postoperatively, no local recurrence or distant metastasis were observed. The range of motion of the left wrist joint was 40 degrees extension, 20 degrees flexion, 45 degrees pronation, and 90 degrees supination (Figure 7). Grip strength was 31.7 kg, which was 91% of that of the healthy side. Hand 20 score (10) was 2.5 points, PRWE-J (patient-rated wrist evaluation questionnaire the Japanese version) score (11, 12) was 8 points, DASH-JSSH (the Japanese version of the disabilities of the arm, shoulder and hand questionnaire) disability/symptom score (13) was 5.8 points, and sports/music score was 0 points. This result indicated that the patient had no difficulty in performing in Kyudo competitions.



**A** **B**

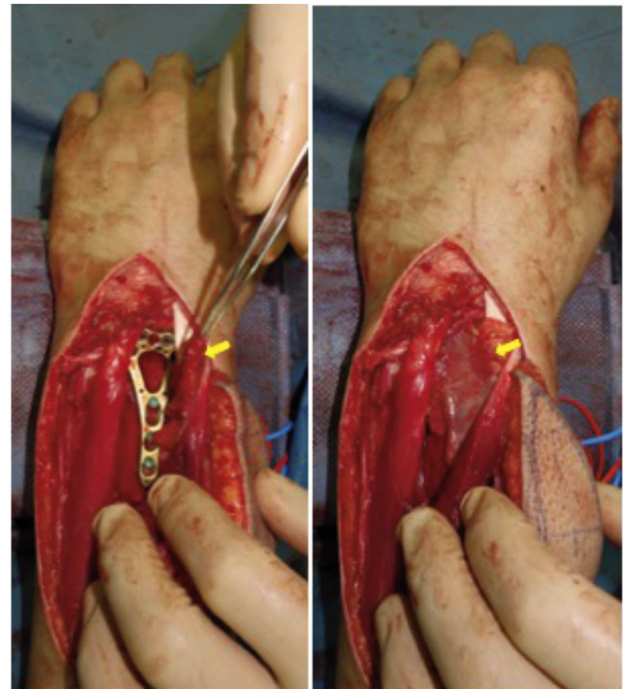


**C**

Figure 2. Intra-surgical image (A, Dorsal side; B, Palmer side) of the distal radial tumor (yellow arrows), which was widely resected (C, the resected osteosarcoma of the distal radius).

## Discussion

FVFG is quite useful for the reconstruction of huge tissue defects after the wide resection of malignant bone tumors of the forearm, because it allows reconstruction of skin and soft tissue defects as well as bone defects concurrently. When the distal radius is resected, reconstruction with FVFG often



**A** **B**

Figure 3. Repairing the extensor tendon gliding surface. The dorsal plate of the distal radius is covered with adipofascial tissue (yellow arrows) and attached to the FVFG [A] before coverage with adipofascial tissue; B) after coverage with adipofascial tissue].

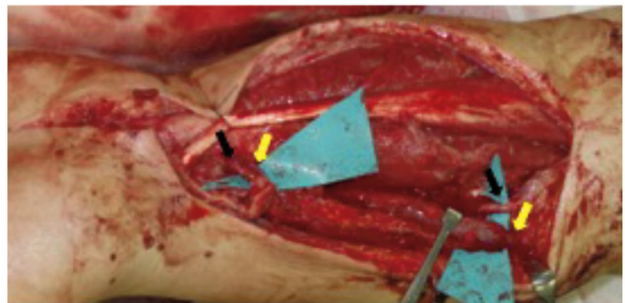


Figure 4. Vascular anastomosis. The peroneal artery is anastomosed to the radial artery in a flow-through fashion (black arrows). The peroneal vein was anastomosed in an end-to-end fashion with the accompanying vein of the radial artery and cephalic vein (yellow arrows).

involves either a fibular head graft to preserve the range of motion of the wrist joint or a total wrist fusion to emphasize stability of the wrist joint (5, 6, 8). The fibular head graft can preserve the range of motion of the wrist joint, but it cannot reconstruct the ligamentous mechanism and thus, cannot provide stability to withstand loads. In addition, the articular surface of the fibula head might collapse in terms of blood

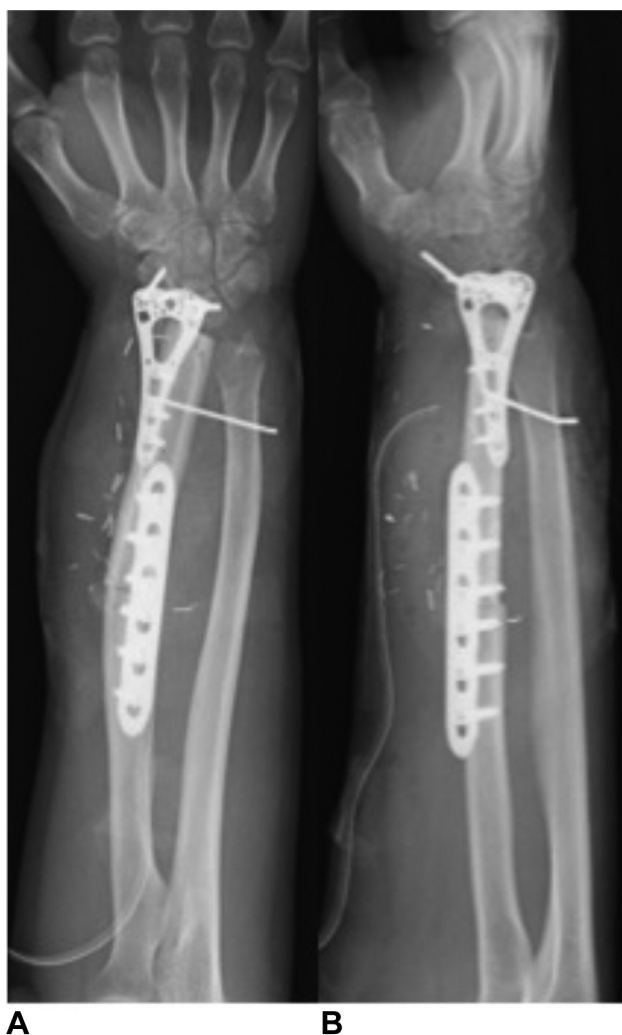

Figure 5. Postoperative forearm X-ray [A] antero-posterior view; B] lateral view].

flow. The partial wrist joint fixation with FVFG has been reported to have excellent clinical results by preserving both the stability and range of motion of the wrist joint (5, 7).

In the present case, the patient was eager to resume Kyudo after the surgery. Thus, we chose partial wrist arthrodesis with FVFG to preserve the range of motion of the wrist joint and fingers as well as the stability of the wrist joint; all of those were quite important for Kyudo. As a result, although palmar flexion of the wrist was inadequate, sufficient extension ability of the left wrist made it possible to preserve sufficient grip strength for Kyudo. Moreover, the preserved range of motion of the wrist enabled fine adjustment of the angle of bow while grasping the bow, and the wrist joint function was well preserved for Kyudo (Figure 8A). The left wrist joint of the Kyudo archer grasping the bow is subjected to the same resilience force as that of squeezing the bow

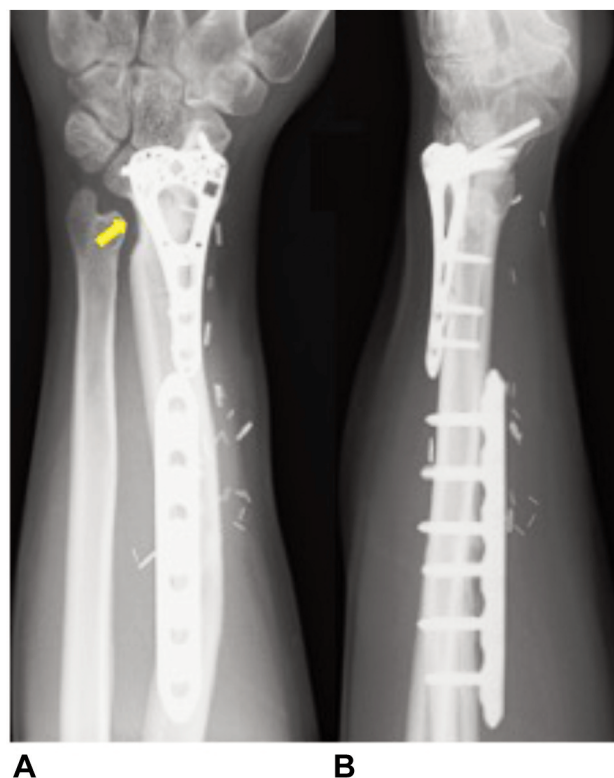


Figure 6. X-ray of the distal radius at 16 months postoperatively [A] antero-posterior view; B] lateral view]. An appropriate gap is created between the ulnar head and grafted fibula (yellow arrow).

when drawing. His wrist had enough stability to draw his Japanese bow, 14 kg of tension weight (Figure 8B).

There are some technical difficulties in our procedure including, the determination of the fixation angle of the wrist joint and to keep appropriate wrist angle and wrist deviation of the axis, the fixation method of the grafted fibula, and the proximal carpal row. The fixation angle of the wrist joint was planned to be 20 degrees of dorsiflexion in order to prioritize grip strength. The distal radio-ulnar ligament and interosseous membrane, including the distal oblique bundle that stabilize the distal radio-ulnar joint (DRUJ) had already been resected, making it very difficult to determine the optimal location of the graft bone that would not interfere with the rotation of the forearm. The ulnar head was preserved for the index of the forearm axis. It was necessary to find the best position to fix the graft without dislocation of the ulna head. It required accurate alignment and a temporary fixation both proximal and distal to the grafted bone. Temporarily, wrist pain occurred at the DRUJ area due to slight interference between the ulnar head and graft bone during rotation postoperatively. Since the bone remodeling of grafted fibula produced an appropriate gap between the ulnar head and grafted fibula up to 16 months postoperatively, the pain around the fibular-ulnar area was relieved (Figure 6A and B).

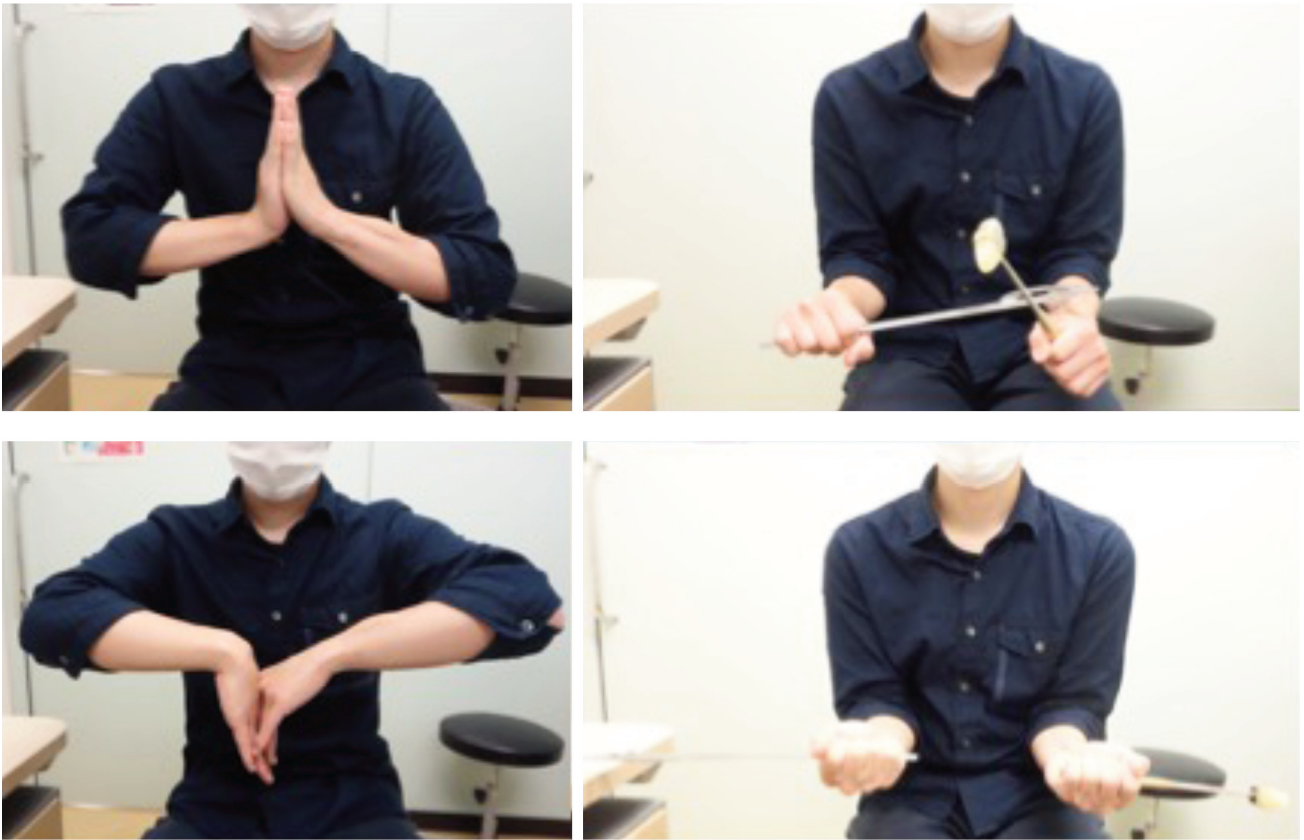

Figure 7. Range of motion of the wrist at 44 months postoperatively. Wrist extension (upper left), wrist extension (lower left), forearm pronation (upper right), and forearm supination (lower right).

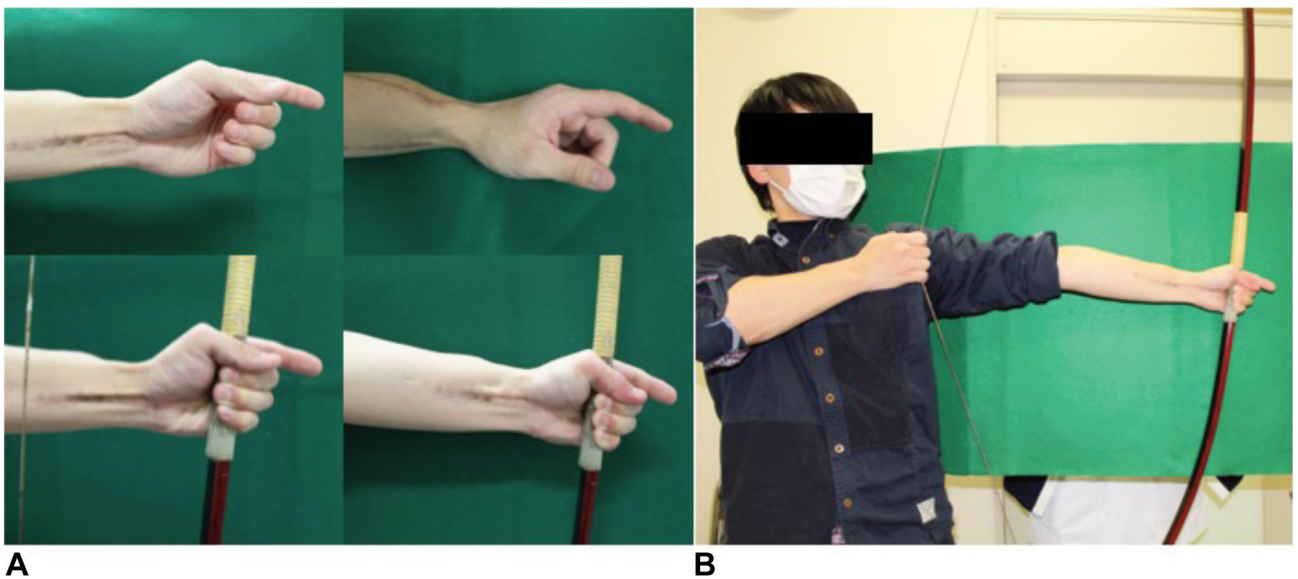


Figure 8. The specific grasp form of Kyudo (A). The reconstructed wrist has adequate stability to draw the Japanese bow (B).

For fixation of the proximal carpal row and distal fibular graft, we used a locking plate designed for distal radius fractures. Recently, a locking plate for distal radius fractures had been reported to be quite useful to fix the radius and proximal carpal row in cases of partial wrist joint fusion for failed distal radius fracture (14). Using a locking plate for distal radius fractures on the dorsal aspect of the wrist joint, distal locking screws can be inserted into the lunate and scaphoid bones. In particular, using the plate for the opposite hand dorsally, longer screws can be inserted into the scaphoid through a screw hole that would normally be inserted into the radial styloid.

Concerning the appropriate bone grafting, the superiority of FVFG from a simple (non-vascularized) fibular graft (15) is still controversial. Although a simple fibular graft alone can result in bone union, FVFG has a great advantage for bone healing (16) in the case of a large bone graft (>6 cm). Even if bone union is achieved, a grafted bone without sufficient blood flow may lead to bone atrophy. However, grafted FVFG observed hypertrophy of the bone at the grafted site, and could have advantages against mechanical loading. Gorski *et al.* showed a mean hypertrophy rate of the FVFG's proximal site of 47% and of the distal site of 32% (17).

Pre- and post-operative chemotherapy and the presence of a large dead space after the wide resection for bone malignancies, increase the risk of surgical site infection. Thus, FVFG has the advantage of being resistant to infection, mostly because of its own blood flow. In addition, FVFG with a large adipofascial flap has the possibility to reconstruct better the gliding floor of the extensor tendon, which contributes to preserving hand function by reducing contractures caused by extensor tendon adhesions. Needless to say, good hand function is essential for maintaining a good QOL of the patient.

Describing the hemodynamics of the fibula, the fibular head is nourished by the anterior tibial artery and the fibular diaphysis is nourished by the peroneal artery. In reconstruction with a fibular head graft, it is difficult to determine which artery to use for the nutrient vessel, the peroneal artery or the anterior tibial artery. If the peroneal artery is selected with an emphasis on bone healing of the fibula with the radius, the blood flow impairment may result in collapse of the fibular head. In contrast, the use of the anterior tibial artery to prioritize blood flow to the fibular head increases the risk of pseudoarthrosis between the fibula and radius (6).

## Conclusion

We reconstructed the upper limb function of a Kyudo archer with osteosarcoma of the distal radius by fibulo-scapho-lunate arthrodesis with FVFG. Preservation of the range of motion and support of the wrist for the Kyudo technique was

achieved. In the present procedure, the palmar locking plate for the distal radius fracture was useful and allowed good fixation of the proximal carpal row and grafted fibula. When reconstructing the bone defect following the resection of distal radial malignancies, partial wrist arthrodesis with FVFG should be considered as the best reconstruction option for function preservation of the hand, if preservation of the midcarpal joint is possible.

## Conflicts of Interest

The Authors state that they have no conflicts of interest to declare in regard to this study.

## Authors' Contributions

NS operated the patient and wrote the manuscript. RK, NT, HY, MH and SK were involved in patient care, manuscript preparation and review. All Authors read and approved the final manuscript.

## Acknowledgements

The Authors are grateful to Dr. Shusa Ohshika (Hiroshima University) for the help with photography and patient follow-up.

## References

- Baumhoer D, Böbling TO, Cates JMM, Cleton-Jansen AM, Hogendoorn PCW, O'Donnell PG and Rosenberg AE: Osteosarcoma. In: WHO Classification of Tumors, 5th Edition. Soft Tissue and Bone Tumors. Lyon, International Agency for Research on Cancer, pp. 403-409, 2020.
- Claxton MR, Shirley MB, Bakri K, Rose PS, Moran SL and Houdek MT: Utility of the free vascularized fibula flap to reconstruct oncologic defects in the upper extremity. *Anticancer Res* 40(5): 2751-2755, 2020. PMID: 32366420. DOI: 10.21873/anticanres.14246
- Yasin NF, Abdul Rashid ML and Ajit Singh V: Survival analysis of osteosarcoma patients: A 15-year experience. *J Orthop Surg (Hong Kong)* 28(1): 2309499019896662, 2020. PMID: 32077796. DOI: 10.1177/2309499019896662
- Unni KK and Inwards CY: Osteosarcoma. In: Dahlin's Bone Tumors, 6th Edition. Philadelphia, Lippincott Williams & Wilkins, pp. 122-157, 2010.
- Minami A, Kato H and Iwasaki N: Vascularized fibular graft after excision of giant-cell tumor of the distal radius: wrist arthroplasty versus partial wrist arthrodesis. *Plast Reconstr Surg* 110(1): 112-117, 2002. PMID: 12087240. DOI: 10.1097/00006534-200207000-00020
- Usui M, Murakami T, Naito T, Wada T, Takahashi T and Ishii S: Some problems in wrist reconstruction after tumor resection with vascularized fibular-head graft. *J Reconstr Microsurg* 12(2): 81-88, 1996. PMID: 8656405. DOI: 10.1055/s-2007-1006458
- Bickert B, Heitmann Ch and Germann G: Fibulo-scapho-lunate arthrodesis as a motion-preserving procedure after tumour resection of the distal radius. *J Hand Surg Br* 27(6): 573-576, 2002. PMID: 12475519. DOI: 10.1054/jhsb.2002.0829

- 8 Lehner B, Jung M and von Stillfried F: [Total wrist fusion with vascularized fibula graft after tumor resection of the distal radius]. *Oper Orthop Traumatol* 24(3): 186-195, 2012. PMID: 22751747. DOI: 10.1007/s00064-011-0102-2
- 9 Landau MJ, Badash I, Yin C, Alluri RK and Patel KM: Free vascularized fibula grafting in the operative treatment of malignant bone tumors of the upper extremity: A systematic review of outcomes and complications. *J Surg Oncol* 117(7): 1432-1439, 2018. PMID: 29513891. DOI: 10.1002/jso.25032
- 10 Suzuki M, Kurimoto S, Shinohara T, Tatebe M, Imaeda T and Hirata H: Development and validation of an illustrated questionnaire to evaluate disabilities of the upper limb. *J Bone Joint Surg Br* 92(7): 963-969, 2010. PMID: 20595115. DOI: 10.1302/0301-620X.92B7.23410
- 11 Omokawa S, Imaeda T, Sawaizumi T, Momose T, Gotani H, Abe Y, Moritomo H and Kanaya F: Responsiveness of the Japanese version of the patient-rated wrist evaluation (PRWE-J) and physical impairment measurements in evaluating recovery after treatment of ulnocarpal abutment syndrome. *J Orthop Sci* 17(5): 551-555, 2012. PMID: 22810808. DOI: 10.1007/s00776-012-0265-1
- 12 Imaeda T, Uchiyama S, Wada T, Okinaga S, Sawaizumi T, Omokawa S, Momose T, Moritomo H, Gotani H, Abe Y, Nishida J, Kanaya F and Clinical Outcomes Committee of the Japanese Orthopaedic Association and the Functional Evaluation Committee of the Japanese Society for Surgery of the Hand: Reliability, validity, and responsiveness of the Japanese version of the Patient-Rated Wrist Evaluation. *J Orthop Sci* 15(4): 509-517, 2010. PMID: 20721719. DOI: 10.1007/s00776-010-1477-x
- 13 Imaeda T, Toh S, Nakao Y, Nishida J, Hirata H, Ijichi M, Kohri C, Nagano A and Impairment Evaluation Committee, Japanese Society for Surgery of the Hand: Validation of the Japanese Society for surgery of the hand version of the disability of the arm, shoulder, and hand questionnaire. *J Orthop Sci* 10(4): 353-359, 2005. PMID: 16075166. DOI: 10.1007/s00776-005-0917-5
- 14 Suzuki D, Maegawa N, Omokawa S, Yajima H and Tanaka Y: Partial wrist arthrodesis with volar locking plate fixation for unfixable distal radius fragility fracture: two case reports. *J Jpn Soc Fract Repair* 38(4): 853-857, 2016.
- 15 Clarkson PW, Sandford K, Phillips AE, Pazonis TJ, Griffin A, Wunder JS, Ferguson PC, Masri BA and Goetz T: Functional results following vascularized versus nonvascularized bone grafts for wrist arthrodesis following excision of giant cell tumors. *J Hand Surg Am* 38(5): 935-940.e1, 2013. PMID: 23455409. DOI: 10.1016/j.jhssa.2012.12.026
- 16 Adani R, Delcroix L, Innocenti M, Marcoccio I, Tarallo L, Celli A and Ceruso M: Reconstruction of large posttraumatic skeletal defects of the forearm by vascularized free fibular graft. *Microsurgery* 24(6): 423-429, 2004. PMID: 15378573. DOI: 10.1002/micr.20067
- 17 Gorski SM, Dong C, Krieg AH and Haug M: Vascularized bone graft reconstruction following bone tumor resection at a multidisciplinary sarcoma center: outcome analysis. *Anticancer Res* 41(10): 5015-5023, 2021. PMID: 34593450. DOI: 10.21873/anticancer.15316

Received March 21, 2022

Revised May 9, 2022

Accepted May 10, 2022